TransForce®2

Arch Developer Appliances
Clinical Cases

New Horizons In Orthodontics

P: 1300 ORDERZ (673 379)
E: sales@naol.com.au

New Horizons In Orthodontics
Transverse and Sagittal Arch Development

William J. Clark
B.D.S., D.D.O., D.D.Sc. F.D.S.R.C.S.Eng.

Dr. William Clark has 50 years experience in orthodontic practice and continues to develop innovative appliances in orthodontic and orthopaedic techniques. He developed Twin Blocks in 1977 and is the author of *"Twin Block Functional Therapy: Applications in Dentofacial Orthopaedics"*, published by Mosby (1995 and, 2002).

Dr. Clark is the first recipient of an award of distinction from the British Orthodontic Society for an outstanding contribution to the specialty of orthodontics. In 2008, he received an award from the International Functional Association for outstanding personal international service to functionalism and orthodontics. In 2010, he completed a thesis on *"New Horizons in Orthodontics & Dentofacial Orthopaedics"* for a D.D.Sc. Degree from the University of Dundee.

Transverse Arch Developer

Sagittal Arch Developer

TransForce^2 Lingual Appliances

The case studies found on the following pages were performed by Dr. Clark. They illustrate the potential of preformed invisible lingual appliances for sagittal and transverse arch development. Light, biological forces generated by enclosed nickel titanium springs achieve an excellent response from patients of all ages, from interceptive treatment in mixed dentition to adult therapy.

TransForce^2 Lingual Appliances integrate with all types of conventional fixed appliances at any stage to simplify treatment. This approach is affordable and efficient, and typically reduces the time required in a fixed appliance by 50%. This is a very important factor, especially in adult therapy. In many cases alignment and arch form can be improved to a stage where invisible finishing appliances may be used to detail the occlusion.

TransForce^2 Appliances are constructed to the highest engineering standards by *Ortho Orgnizers®*, advancing the future of orthodontics. They do not cover the palate and are comfortable to wear, so patients of all ages appreciate the advantages of *TransForce^2* Appliances.

Ease of Insertion
Placement blades are designed to insert easily into molar bands with standard .036" x .072" lingual sheaths

Aesthetic Appearance
Lingual placement for a virtually invisible appearance

Size Identification
Color-coded for easy identification

Optimum Patient Comfort
Nitanium® Coil Springs enclosed in expansion modules provide slow continuous force

No Laboratory Work Required
Select and order appliance by desired finish size

Less Inventory
Universal sizes for upper or lower arches – no need to carry separate inventory

Zero Patient Compliance
Appliance allows for up to 2 mm expansion every 6-8 weeks with minimum maintenance

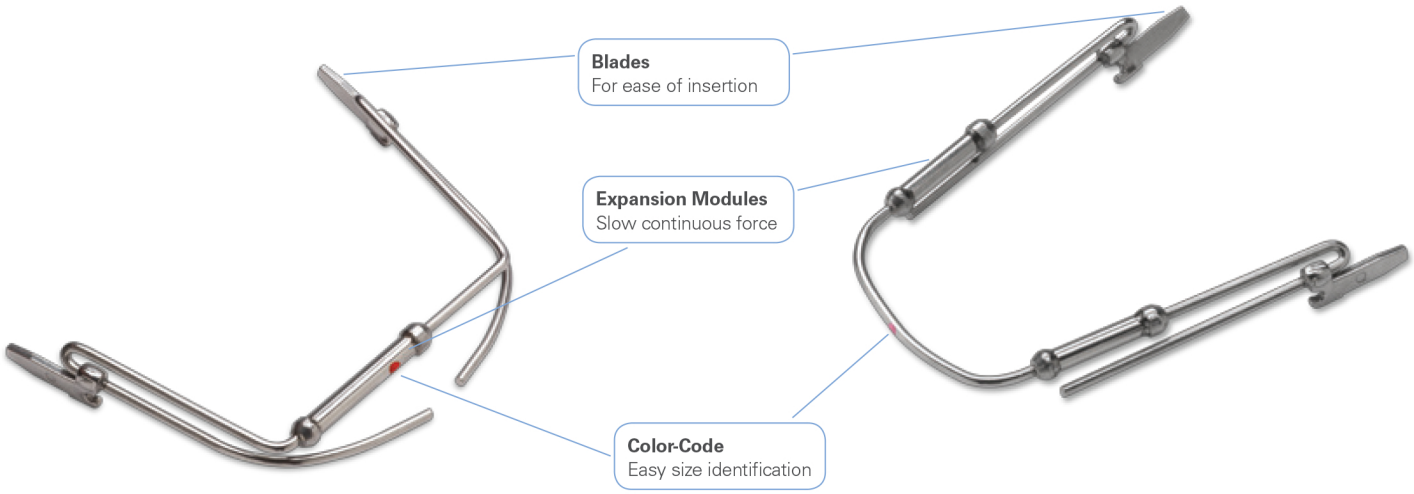

TRANSVERSE ARCH DEVELOPMENT

Occlusion Before Treatment

Before Treatment | **5 Months Treatment** | **Out of Retention**

Occlusion After Treatment

Rapid improvement by maxillary arch development with a Transverse Expander corrected the crossbite and improved arch form in this case. After five months of treatment the Transverse Expander was kept in place for an additional three months. The final photographs show the occlusion and arch form four years later following 10 months of additional treatment with an upper fixed appliance.

TRANSVERSE AND SAGITTAL ARCH DEVELOPMENT

Occlusion Before Treatment

Before Treatment | **After Transverse Expansion** | **After Arch Development**

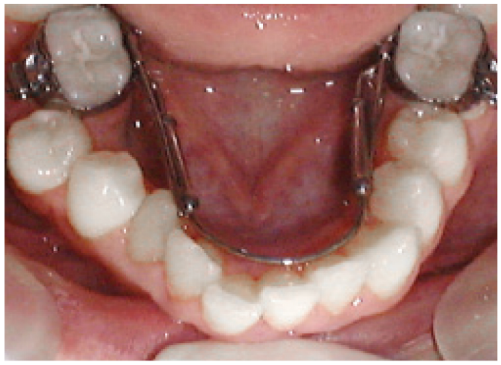

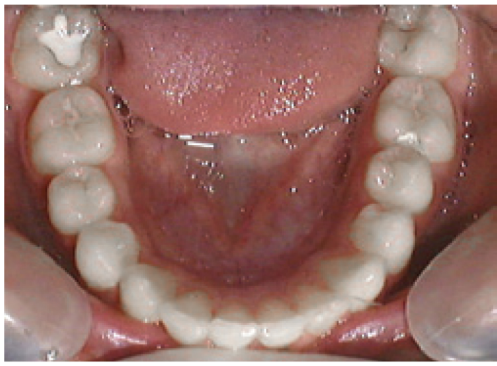

Occlusion After Treatment

In this case, the patient was unwilling to have fixed appliances, but was happy to wear lingual appliances. Upper Transverse and lower Sagittal Appliances were used and as treatment progressed the patient agreed to have a lower fixed appliance fitted. This severe malocclusion was not treated to an ideal result, but showed a marked improvement with simple treatment followed by the use of retainers.

SAGITTAL ARCH DEVELOPMENT

Six Months Treatment

Before Treatment

After *TransForce* Saggital

Invisible Retainers

After Retention

This adolescent patient was treated entirely by *TransForce*[2] Sagittal Appliances, followed by invisible retainers. Lingually inclined upper and lower incisors responded well to treatment with lingual *TransForce*[2] Appliances to correct the arch form. This approach would apply equally to adult treatment of this type of malocclusion, followed by fixed lingual retainers.

TREATMENT OF LABIAL CROWDING

Before Treatment

4 Months Treatment

After Arch Development

In this case, rapid improvement by maxillary arch development with a Transverse Expander allowed efficient progression to fixed appliances over a period of five months with appointments at 10 week intervals. Final photographs were taken three years later.

ADULT THERAPY – ARCH DEVELOPMENT

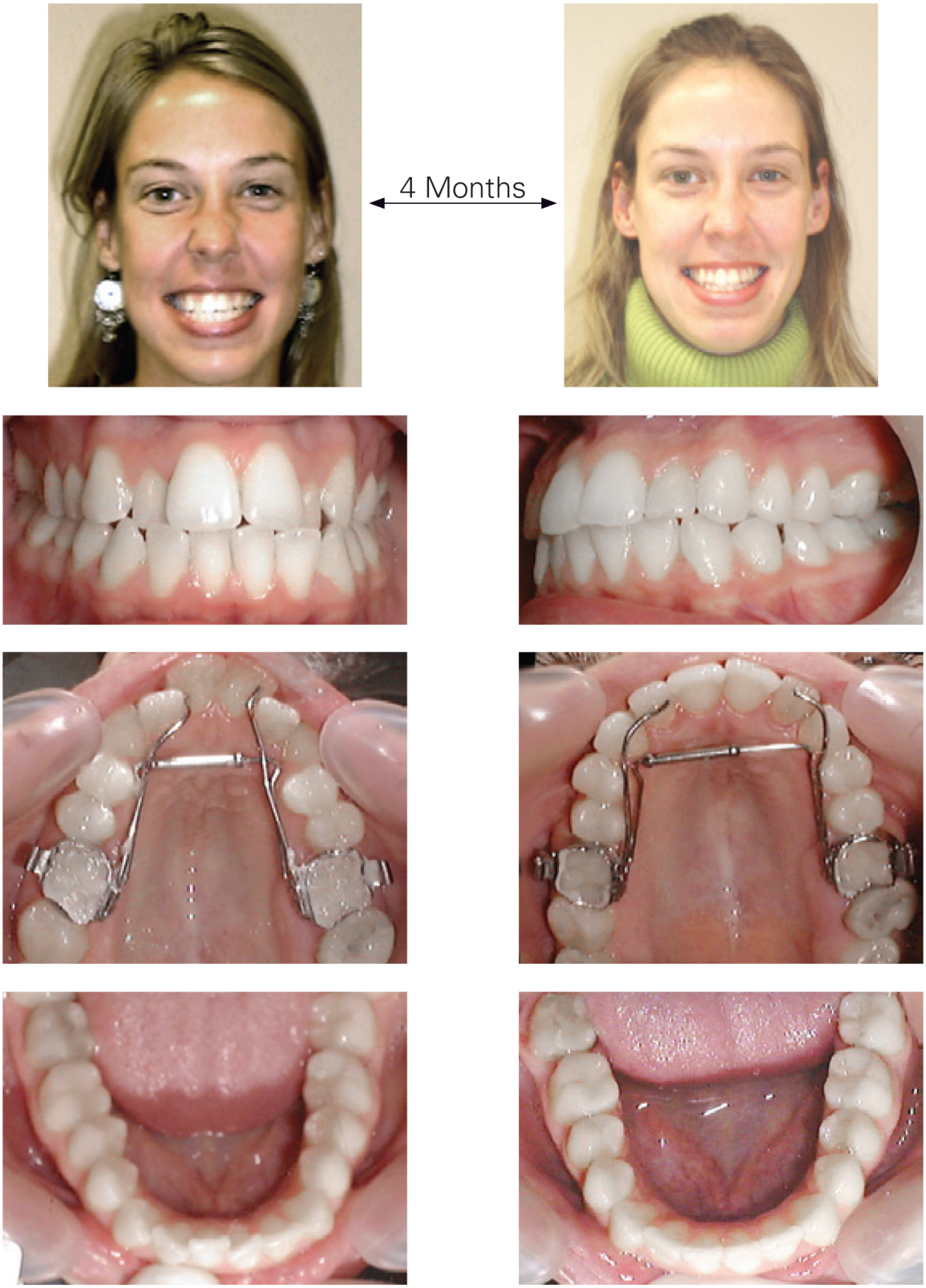

This young adult with severe maxillary contraction was treated with *TransForce*[2] Appliances for lingual arch development. She enjoyed having invisible appliances for 11 months while her smile noticeably improved before proceeding with aesthetic fixed appliances to complete treatment.

FIXED APPLIANCES TO COMPLETE TREATMENT

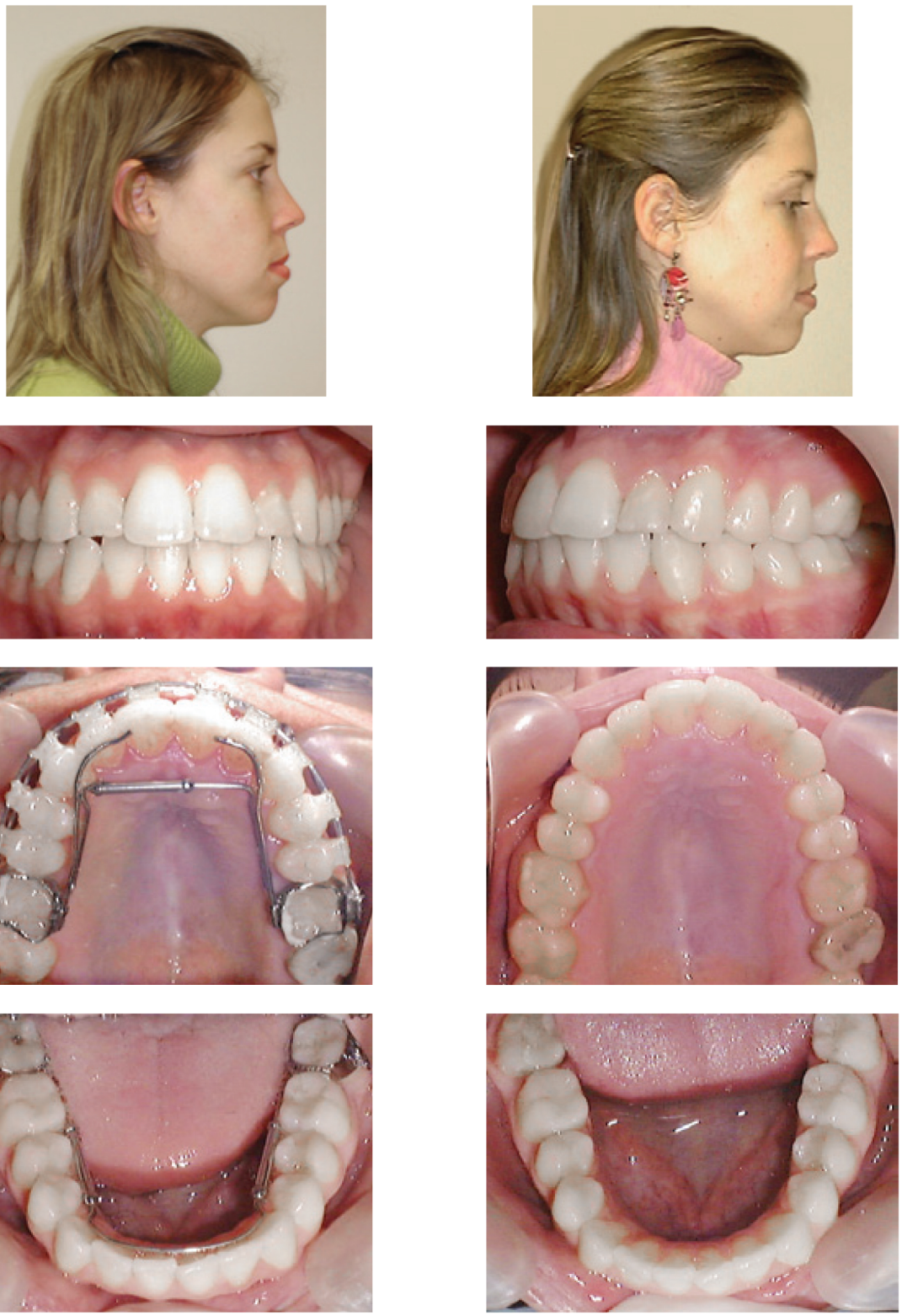

The lingual approach presents minimum discomfort and inconvenience for adults. Invisible lingual appliances simplify treatment using biocompatible forces for gentle arch development. Typically the time in fixed appliances is reduced by 50%. In this case, treatment was completed in 19 months.

TRANSVERSE TRANSFORCE² APPLIANCES

8 Months

This eight year old girl presented with a Class III malocclusion with severe upper labial crowding treated in mixed dentition with upper and lower *TransForce²* Transverse Expansion Appliances. Active treatment was completed in eight months, and the *TransForce²* Appliances remained in place for three months to retain.

FIXED APPLIANCES TO DETAIL OCCLUSION

After *TransForce*[2] Appliance retention, there was a period of observation while waiting for eruption of permanent teeth. This was followed by a short period of treatment with fixed appliances at age 11 to detail the occlusion. Interceptive treatment in mixed dentition to resolve anterior crowding simplified the finishing stage.

CLASS III SAGITTAL TRANSFORCE^2 APPLIANCE

This demonstrates interceptive treatment for a Class III malocclusion in mixed dentition with an upper Sagittal *TransForce*^{2} Appliance. The lingual occlusion was corrected after three months, and the appliance was used as a retainer for an additional six months.

CLASS III SAGITTAL TRANSFORCE^2 APPLIANCE

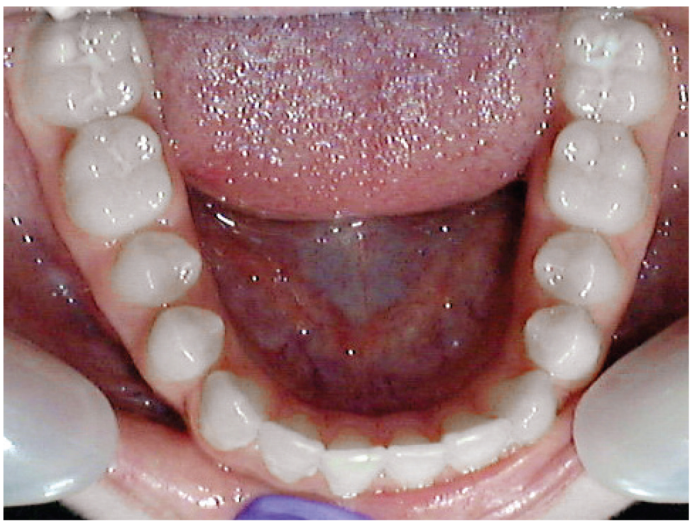

No further treatment was required and the final photographs show the occlusion and arch form three years after eruption of permanent teeth. The profile and facial balance has improved after a short period of interceptive treatment with a Sagittal *TransForce*^{2} Appliance.

PHASE 1 – TRANSVERSE ARCH DEVELOPMENT

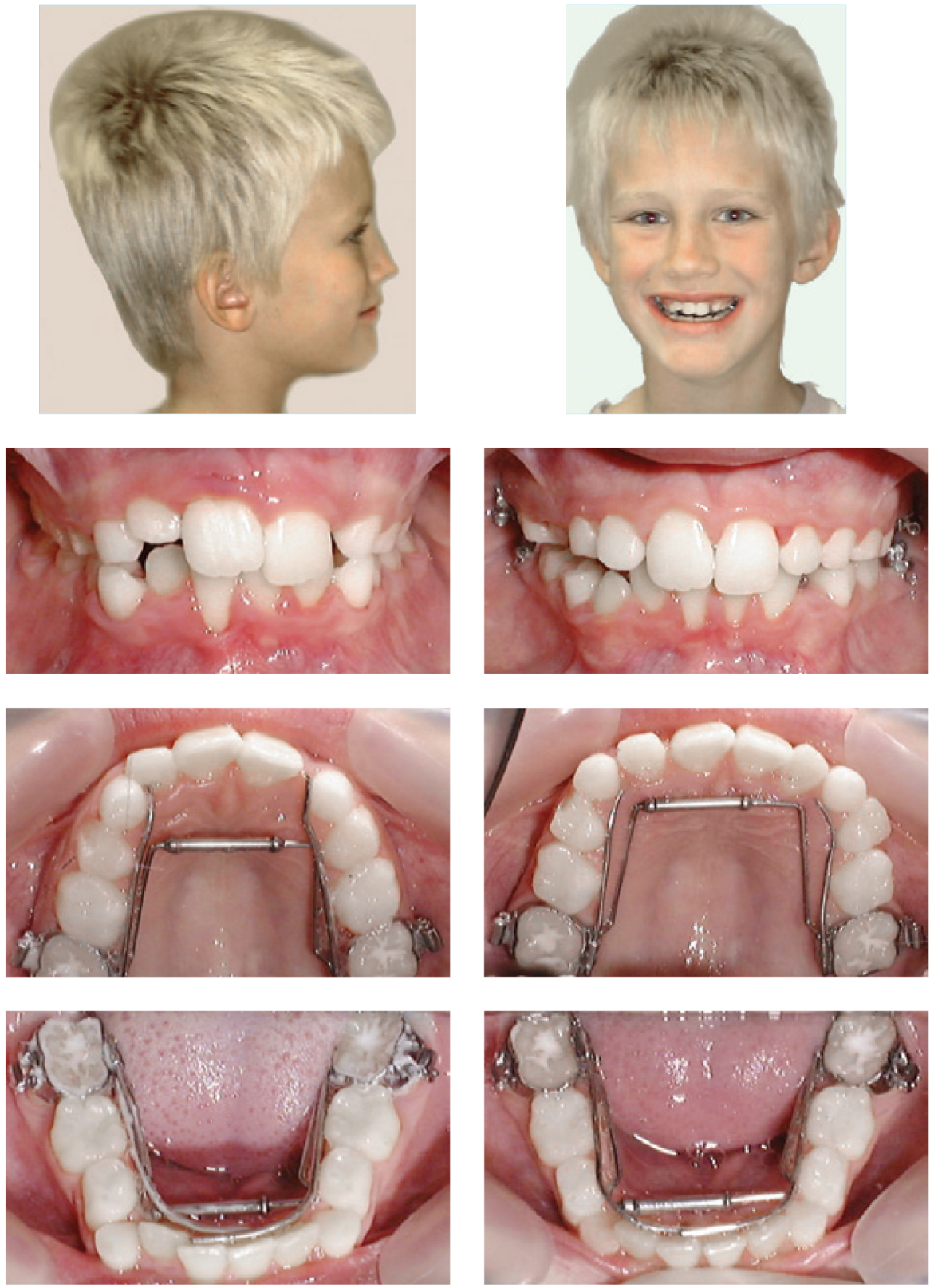

A Class II Division 2 malocclusion with severe maxillary contraction was treated with Transverse *TransForce*[2] Appliances to accommodate the unerupted upper lateral incisor. The incisor erupted after 12 months and the appliances acted as retainers for an additional six months.

SAGITTAL ARCH DEVELOPMENT

After eruption of permanent teeth *TransForce*[2] Sagittal Appliances correct slight residual crowding, followed by a lower fixed appliance for six months. No upper fixed appliance was required. Interceptive treatment with invisible lingual appliances simplified correction of this malocclusion.

ARCH DEVELOPMENT IN ADULT THERAPY

TransForce[2] Lingual Appliances can be combined with fixed appliances to enhance arch development in adult therapy. This may be the first step in treatment to make space to align a crowded labial segment before placing brackets. The patient benefits by wearing invisible appliances in the first phase of treatment, while also reducing the time spent in full-fixed appliances.

CARRIERE® SELF-LIGATING BRACKETS

The *Carriere* Self Ligating Bracket System is a highly efficient mechanism to detail the occlusion and deliver precision at the end of treatment. The brackets have a secure locking mechanism and are low profile, providing improved patient comfort, and delivering light, controlled forces throughout treatment. Treatment was completed in two years followed by fixed lingual retainers.

ARCH DEVELOPER APPLIANCES

ITEM	DESCRIPTION

*TransForce*² Transverse Arch Developer

The Transverse Appliance has an expansion module to increase the inter-canine width (expands at the cuspids) and may be used in the upper or lower arch when expansion is required to accommodate crowding in the labial segments, or to correct arch width in constricted arches.

CATALOG NUMBER	COLOR-CODE	TRANSVERSE SIZE: INTER-CANINE FULLY EXTENDED	TRANSVERSE SIZE: INTER-CANINE FULLY COMPRESSED	MAXIMUM AMOUNT OF EXPANSION
424-500		Transverse Kit		
424-526	Red	26 mm	18 mm	8 mm
424-528	Green	28 mm	20 mm	8 mm
424-530	Purple	30 mm	22 mm	8 mm
424-532	Pink	32 mm	24 mm	8 mm

Transverse Arch Development Planner 424-500T

*TransForce*² Sagittal Arch Developer

The Sagittal Appliance is specifically designed for anterior arch development (creates space by advancing the 3x3 labially) and is often indicated for simultaneous use in both arches. The appliance operates on the slide principle and may be used unilaterally or bilaterally to extend arch length.

CATALOG NUMBER	COLOR-CODE	SAGITTAL SIZE: ANTERIOR-POSTERIOR FULLY EXPANDED	SAGITTAL SIZE: ANTERIOR-POSTERIOR FULLY COMPRESSED	MAXIMUM AMOUNT OF EXPANSION
424-700		Sagittal Kit		
424-728	Green	28 mm	24 mm	4 mm
424-730	Purple	30 mm	26 mm	4 mm
424-732	Pink	32 mm	28 mm	4 mm
424-734	Blue	34 mm	30 mm	4 mm
424-736	Black	36 mm	30 mm	6 mm
424-738	Yellow	38 mm	32 mm	6 mm
424-740	White	40 mm	34 mm	6 mm

Sagittal Arch Development Planner 424-700T